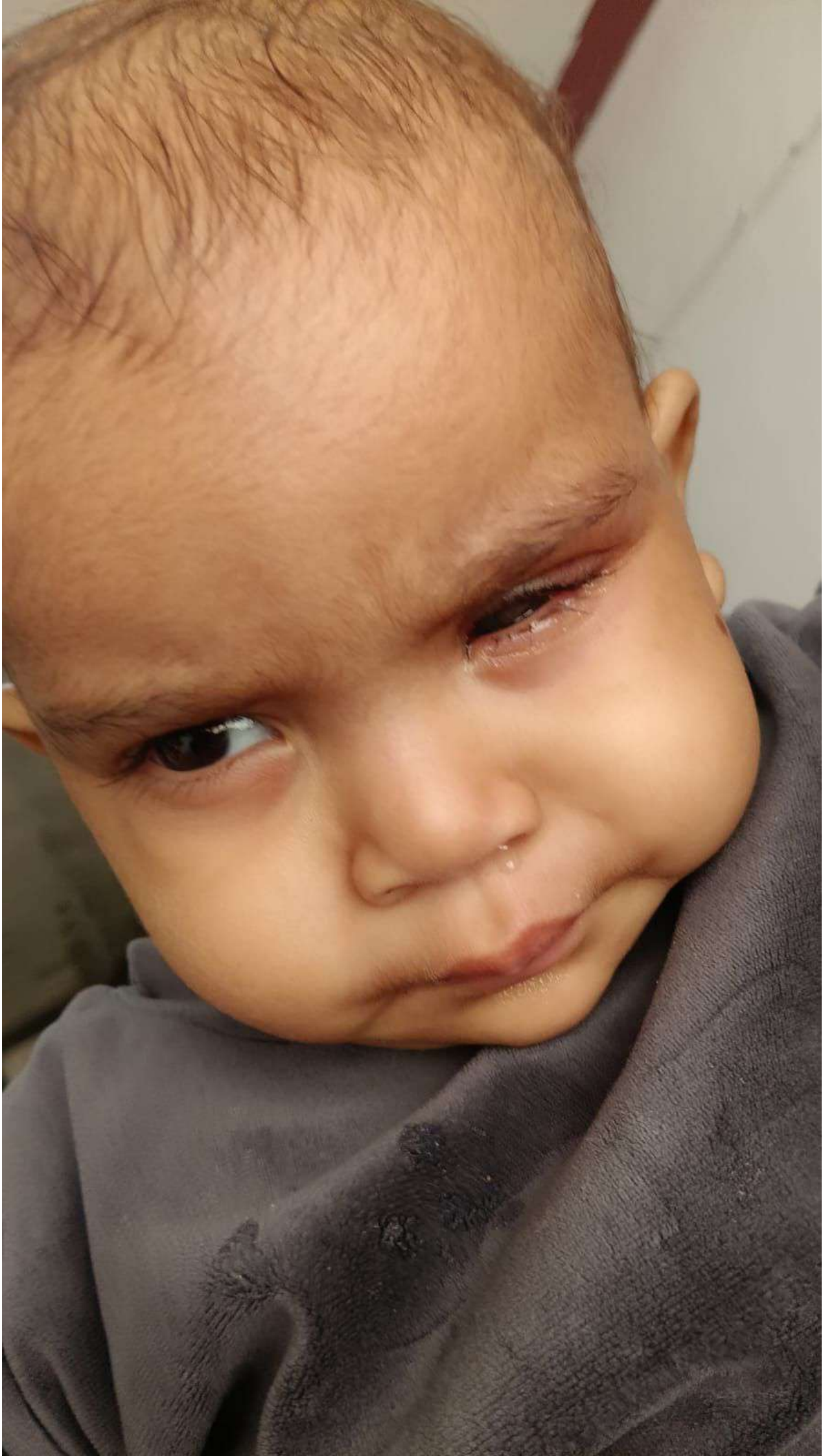

ब. रो. वि. कार्ड O.P.D. Card



अनुभाग व दिन
Section and Day **IV**
सोमवार व बृहस्पतिवार
Monday & Thursday

कमरा नंबर
Cabin No.

डा. राजेन्द्र प्रसाद नेत्र विज्ञान केन्द्र
अ. भा. २

Dr. Rajen
A.I.M.S.

यू.एच.आ.
UHID N

रो
Name

UHID: 108769728
AEIHA
Dept No: 3076059140347

वैभव कुमार / VAIBHAV KUMAR

S.O. VI. VY NADIT
D. S. D. H. J. G. R. H. N. B. H. A. R. K. I. A. N. D. S. I. S. T. I. T. U.

MR. B. 31207774 General Ex-0
Follow Up Patient

असुर / Queue 9
कमरा / Room: 43
Unit IV
RPG OPD

Dr. Bheema Chavla

MON. THU
OPD



Registration time:
02/02/2026 09:51:35 AM

पता
Address

26A

Soc 476/26

दिनांक DATE	निदान DIAGNOSIS	उपचार Treatment
02 FEB 2026	<p><i>Ad</i></p> <p><i>metastatic carcinoma</i></p> <p><i>chemotherapy</i></p> <p><i>- ECA after 4th cycle</i></p> <p><i>DIF ECA after 4 weeks</i></p> <p><i>37A for stage 14</i></p> <p><i>14/2/2026</i></p> <p><i>675th floor</i></p> <p><i>7230 an</i></p>	<p><i>Phary</i></p>

Vnt 648
Camat
in contact
25/26
cardst

कृपया इस कार्ड को सुरक्षित रखें तथा अस्पताल में दिखाने के समय हर वक्त साथ लायें।
Kindly keep this Card safely and bring it on your follow-up visits.

- धूम्रपान निषेध 1. No Smoking
- कूड़ा कर्कट केवल कूड़ेदान में ही डालें 2. Use Dustbin
- थुकिये नहीं 3. No Spitting



फॉर्म 1
S.No.1



झारखंड सरकार

GOVERNMENT OF JHARKHAND
DEPARTMENT OF ECONOMICS & STATISTICS
COMMUNITY HEALTH CENTERS MADHUPUR
COMMUNITY HEALTH CENTERS MADHUPUR

फॉर्म 5
FORMS



जन्म प्रमाण-पत्र
BIRTH CERTIFICATE

(जन्म और मृत्यु रजिस्ट्रीकरण अधिनियम, 1969 की धारा 12/17 तथा झारखंड जन्म और मृत्यु रजिस्ट्रीकरण नियम 2009 के नियम 8/13 के अंतर्गत जारी किया गया)
(ISSUED UNDER SECTION 12/17 OF THE REGISTRATION OF BIRTHS AND DEATHS ACT, 1969 AND RULE 8/13 OF THE JHARKHAND REGISTRATION OF BIRTHS & DEATHS RULES 2009)

यह प्रमाणित किया जाता है कि निम्नलिखित सूचना जन्म के मूल लेख से ली गई है जो कि COMMUNITY HEALTH CENTERS MADHUPUR सहस्रील मधुपुर जिला देवघर राज्य/संघ प्रदेश झारखंड, भारत के रजिस्टर में उल्लिखित है।

THIS IS TO CERTIFY THAT THE FOLLOWING INFORMATION HAS BEEN TAKEN FROM THE ORIGINAL RECORD OF BIRTH WHICH IS THE REGISTER FOR COMMUNITY HEALTH CENTERS MADHUPUR OF TAHSIL/BLOCK MADHUPUR OF DISTRICT DEOGHAR OF STATE/UNION TERRITORY OF JHARKHAND, INDIA

नाम / NAME: VAIHNAV KUMAR / वैभव कुमार

लिंग / SEX: MALE / पुरुष

आधार संख्या / AADHAAR NUMBER:

जन्म तिथि / DATE OF BIRTH:

02-10-2024

SECOND-OCTOBER-TWO THOUSAND TWENTY FOUR

जन्म स्थान / PLACE OF BIRTH:

COMMUNITY HEALTH CENTERS MADHUPUR, KUSHMAHA,
MADHUPUR, DEOGHAR, JHARKHAND / COMMUNITY HEALTH CENTERS
MADHUPUR, KUSHMAHA, मधुपुर, देवघर, झारखंड

माता का नाम / NAME OF MOTHER:

GUNJAN KUMARI / गुंजन कुमारी

पिता का नाम / NAME OF FATHER:

VIJAY NAIT / विजय नाथ

माता का आधार नंबर / AADHAAR NUMBER OF MOTHER:

XXXX-XXXX-7330

पिता का आधार नंबर / AADHAAR NUMBER OF FATHER:

XXXX-XXXX-6927

बच्चे के जन्म के समय माता-पिता का पता / ADDRESS OF PARENTS AT THE TIME OF BIRTH OF THE CHILD:

GRAM - CHARPA, POST - CHARPA, CHARPA, MADHUPUR, DEOGHAR,
JHARKHAND, 815353 / ग्राम - चरपा, पोस्ट - चरपा, चरपा, मधुपुर, देवघर, झारखंड,
815353

माता-पिता का स्थायी पता / PERMANENT ADDRESS OF PARENTS:

GRAM - CHARPA, POST - CHARPA, CHARPA, MADHUPUR, DEOGHAR,
JHARKHAND, 815353 / ग्राम - चरपा, पोस्ट - चरपा, चरपा, मधुपुर, देवघर, झारखंड,
815353

पंजीकरण संख्या / REGISTRATION NUMBER:

B202520690830000674

पंजीकरण दिनांक / DATE OF REGISTRATION:

11-02-2025

टिप्पणी (यदि कोई हो) / REMARKS (IF ANY):

जारी करने की तिथि / DATE OF ISSUE:

12-09-2025

Updated On : 11-02-2025 14:32:26



'This QR code can be used to check the authenticity of the certificate'



[Handwritten Signature]

प्राधिकारी के हस्ताक्षर / SIGNATURE OF ISSUING AUTHORITY :

रजिस्ट्रार (जन्म एवं मृत्यु)

Registrar (BIRTH & DEATH)

COMMUNITY HEALTH CENTERS MADHUPUR
COMMUNITY HEALTH CENTERS MADHUPUR

"प्रत्येक जन्म एवं मृत्यु का पंजीकरण सुनिश्चित करें / ENSURE REGISTRATION OF EVERY BIRTH AND DEATH"



भारत सरकार
Government of India



Aadhaar No. Issued: 03/11/2011



विजय नापित

Vijay Napit

जन्म तिथि / DOB : 25/01/1993

पुरुष / Male



आधार पहचान का प्रमाण है, नागरिकता या जन्मतिथि का नहीं।
इसका उपयोग सत्यापन (ऑनलाइन प्रमाणीकरण, या क्यूआर कोड/
ऑफलाइन एक्सएमएल की स्कैनिंग) के साथ किया जाना चाहिए।

Aadhaar is proof of identity, not of citizenship
or date of birth. It should be used with verification (online
authentication or scanning of QR code / offline XML).

2122 1118 6927

मेरा आधार, मेरी पहचान

Scanned with JAEIN Scanner



भारतीय विशिष्ट पहचान प्राधिकरण

Unique Identification Authority of India



Details as on 06/08/2024

पता: S/O दुर्योधन नापित, वार्ड संख्या ०८,
डारुघर/चा प- चरपा, पंचायत- मधुपुर, चरपा,
टीवघर, झारखण्ड, 815353

Address: S/O Duryodhan Napit, Ward No 08,
Post/G P- Charpa. Block- Madhupur,
Charpa, DIST Deoghar, Jharkhand, 815353



2122 1118 6927



1947

help@uidai.gov.in

www.uidai.gov.in



MIS 2022-0134

PATIENT'S NAME: VAIBHAV KUMAR	AGE/SEX: 1Y2M/M
REF. BY: AIIMS	REG./UID: VAR0256
TEST NAME: 3T MRI SCAN - CEMRI HEAD & ORBITS	EXAM. DATE: 22-DEC-2025

CONTRAST MRI BRAIN WITH ORBIT

TECHNIQUE:

MRI of the brain and orbits was performed with standard sequences in axial, coronal, and sagittal planes before and after intravenous contrast administration (4 ml). No contrast reaction is noted.

Clinical Details: Known case of bilateral retinoblastoma.

FINDINGS:

Orbits:

Left Eyeball: There is evidence of a heterogeneously enhancing altered signal intensity lesion measuring 20 x 14 mm in the posterior chamber of the left eyeball, showing internal foci of calcification. No evidence of extraocular extension. No involvement of the left optic nerve.

Right Eyeball: There is a heterogeneously enhancing plaque-like altered signal intensity lesion measuring approximately 6 x 3 mm in the temporal region of the posterior chamber of the right eyeball. No evidence of extraocular extension. No involvement of the right optic nerve.

Optic Nerves: No abnormal thickening or enhancement of the bilateral optic nerves. No intraorbital or intracanalicular extension seen.

Extraocular Muscles: Appear normal bilaterally.

Retrobulbar Fat: Preserved bilaterally.

Lacrimal Glands: Appear normal bilaterally.

Orbital Walls: Appear intact bilaterally.

Sinuses: Clear.

Brain Parenchyma:

No focal lesions or abnormal signal intensities are seen in the cerebral hemispheres, brainstem, or cerebellum. No evidence of leptomeningeal enhancement. Ventricular system is normal in size and configuration. No evidence of hydrocephalus. Basal ganglia, thalami, and internal capsules are unremarkable.

Sellar and Parasellar Region:

Pituitary gland and stalk are normal in size and signal. No abnormal enhancement or mass lesion.

Brainstem and Cerebellum:

Normal in morphology and signal intensity. No abnormal enhancement.

Cerebrospinal Fluid Spaces:

Basal cisterns and cortical sulci are within normal limits for age. No evidence of abnormal extra-axial collections.

Disclaimer: : It is an interpretation of medical imaging/diagnostic based on clinical data. All modern machines/procedures have their own limitation. This is neither complete nor accurate; hence, findings should always be interpreted in the light of clinico-pathological correlation. This is a professional opinion, not a diagnosis. Not meant for medico legal purposes. Any typographical error should be informed and report sent for correction within 7 days.





MIS 2022-0134

PATIENT'S NAME: VAIBHAV KUMAR	AGE/SEX: 1Y2M/M
REF. BY: AIIMS	REG./UID: VAR0256
TEST NAME: 3T MRI SCAN - CEMRI HEAD & ORBITS	EXAM. DATE: 22-DEC-2025

Major Vessels:

Major intracranial vessels appear normal in course and caliber. No abnormal flow voids or vascular malformations seen.

Other Incidental Findings:

No other significant abnormalities detected.

IMPRESSION:

- Heterogeneously enhancing altered signal intensity lesion measuring 20 x 14 mm with internal foci of calcification in the posterior chamber of the left eyeball, without extraocular or optic nerve extension, likely retinoblastoma.
- Heterogeneously enhancing plaque-like altered signal intensity lesion measuring approximately 6 x 3 mm in the temporal region of the posterior chamber of the right eyeball, without extraocular or optic nerve extension, likely retinoblastoma.
- No evidence of intracranial extension or associated brain parenchymal abnormality.

ADVICE: CLINICAL CORRELATION.

Dr. Sacchidanand Purkait Chief Consultant Radiologist	Dr. K. K. MISHRA Consultant Radiologist	Dr. Bhavesh Patel Consultant Radiologist	Dr Rahul Bhartiya Consultant Radiologist
--	--	---	---

Disclaimer: : It is an interpretation of medical imaging/diagnostic based on clinical data. All modern machines/procedures have their own limitation. This is neither complete nor accurate; hence, findings should always be interpreted in the light of clinico-pathological correlation. This is a professional opinion, not a diagnosis. Not meant for medico legal purposes. Any typographical error should be informed and report sent for correction within 7 days.





अ० भा० आ० सं० अस्पताल / A.I.I.M.S. HOSPITAL
बहिरंग रोगी विभाग / Out Patient Department



अस्पताल के अन्दर धूम्रपान मना है। / SMOKING IS PROHIBITED IN HOSPITAL PREMISES

कठोरपणं चतुर्ण्युषणम्

OPR-6

एकक/Unit III

विभाग/Dept. Med Onco

ब०रो०नि० पंजीकृत सं०/O.P.D. Regn. No. 108769728

नाम/Name	पिता/पुत्र/पत्नी/पुत्री F / S / W / D of	लिंग Sex	आयु Age	पता/Address
Vaibhav Kumar		ly	Male	

निदान/Diagnosis

दिनांक/Date	उपचार/Treatment
<p><u>01/12/2015</u></p> <p> </p> <p>EVA:</p> <p>⊖ - N/Aclacten union.</p>	<p> <ul style="list-style-type: none"> • white eye reflex } x Smo of age. • Buphthalmos in ⊖ • cough x 3 days • No eye - headache monitoring / FND • NO H/O RB in family. </p> <p> <u>O/E:</u> PR: 120/m RR: 50/m PP/LP: w/p Peripherals: wam CRT < 3sec 4E: ⊖ eye Buphthalmos 2 Squint ⊕ </p> <p> P+I = cy⁻ L⁻ E⁻ </p> <p> Chest: B/L wheeze ⊕ B/L HE ⊕ SCR ⊕ / ICR ⊕ </p> <p> COS: ⊖ S1, S2 heard Tachycardia ⊕ </p> <p> <u>Adv s.</u> → Neb z citalin 1.5mg z 3ml NS at 0, 20min, 40min. → Neb z budesone 1.25mg / 3ml NS q12h. → outside CCT boxin + orbit for discussion. </p>

PO SR shall
Review

LC0212251426 108769728



LH02122500920 108769728



Mr VAIBHAVKUMAR

का यही संकल्प, स्वच्छता से काया कल्प / CLEAN AND GREEN AIIMS

जीवन का बहुमूल्य उपहार / ORGAN DONATION - A GIFT OF LIFE

3, 26588360, 26593444, www.orbo.org Helpline - 1060 (24 hrs service)



meraaspatal.nhp.gov.in

- CE-MRI Brain + orbit to be done.
 - CBC/RA/UF/ HbAg/Anti HCV → Smart lab.
 - HW - Gate no. I
 - Mantoux - 205. — Reading on 4/12/25 at 10am
 - RPC - To kindly provide the exact grouping of the (L) Eye disease. — Ward 2A
 - N/V in OPD - 3/12/25 = reports.
- Shivan
SR

3/12/25. (L) Eye RB - Grouping Pending.

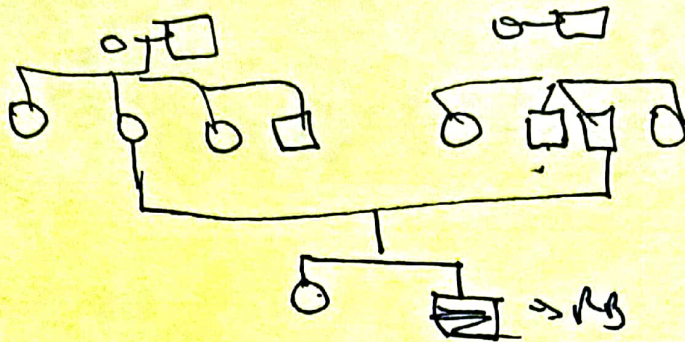
- Adv:
- CE-MRI Brain + orbit.
 - QR labs.
 - RPC - kindly provide exact grouping of (L) eye disease.

→ cont. neb. = Asthalin/ neb = Budecort x 3 days

→ cont. nasoclear.

→ N/V in OPD on 6/12/25 = reports

|
Shivan
SR



No Family Hx

FEVA

Rz 20/20

Du zahi

29/11/25

7th floor

at 7:30am NPO explained ghusali khus khus

Wala for bus

Sat. 05

MRI orbit & brain
T1 & T2 weighted
ECE MRI images

2 coronal sections through optic nerve & pineal gland

Per

for MRI T2 wdw
on 2/12/25 (53) 10am
at 10am MRI for

CE MRI brain & orbit T1 & T2

weighted images in sagittal, axial & coronal planes

2mm

cut sections through optic nerve & pineal gland (fat suppressed)

26/11/25

नेत्र ईश्वरीय सर्वश्रेष्ठ उपहार है जिनका मनुष्य जीवन में दान करना परमश्रेष्ठ है।

इनकी पूर्ण रक्षा कीजिए ताकि ये आपकी रक्षा कर सकें।

Eyes are God's most precious gift to man kind and eye donation is the most noble deed.

Take full care of them so that they can take care of you.

ब० रो० वि० कार्ड

दृष्टि

अनुभाग व दिन
Section and Day
बुधवार व शनिवार
Wednesday & Saturday

कमरा नंबर
Cabin No.

UHID: 108769728
ABHA:
Dept No: 20250050140242

मंथाना / Queue 2:
कमरा / Room: 17A
Unit-II

वेभव कुमार / VAIBHAV KUMAR

S/O VIJAY NAPI
1Y / M पुरुष
EAST DEOGARH JHARKHAND, INDIA

Mob: 982237273 General Rx
New Patient

REGISTRATION TIME
28/11/2025 09:40:48 AM

आयु Age	पता Address
------------	----------------

दिनांक DATE	निदान DIAGNOSIS
----------------	--------------------

VA <) Follows objects
② Does not follow object

उपचार Treatment
outside Assoc - (B) RB

no leucocoria x smouths.

O/E - (R) A/S-WNL
(L) Enlarged corneal diameters
& retroental vessels visible.

CECT <) (R) Hyperechoic mass & calcifications s/o RB
(21/11/25) 26/11/25

(R) INFERIOR RETINAL MASS (+)
(L) LARGE MASS OCCUPYING VITREOUS CAVITY

(1428) Dr. Kalyajini plz

DR. SATYARAB

FT / NVD / No NICU stay
No similar family history

(R) Debate

कृपया इस कार्ड को सुरक्षित रखें तथा अस्पताल में दिखाने के समय हर वक्त साथ लायें।
Kindly keep this Card safely and bring it on your follow-up visits.

1428
RB Clinic
Registration
Wed

1. धूम्रपान निषेध No Smoking
2. कूड़ा कर्कट केवल कूड़ेदान में ही डालें Use Dustbin
3. थूकिये नहीं No Spitting

अखिल भारतीय आयुर्विज्ञान संस्थान / ALL INDIA INSTITUTE OF MEDICAL SCIENCES

एन.एम.आर. विभाग / DEPARTMENT OF N.M.R.

नैदानिक एम. आर.आई मांग प्रपत्र / CLINICAL MRI REQUISITION FORM

1. Clinical Dept or Unit IV Date of Requisition 2/19/25
OPD No 108769728 CR No Ward / Bed No.

2. Screening Dept. : Radio-diagnosis [checked] Neuro-Radiology [] Cardiac Radiology []
(Tick as appropriate)

3. रोगी का नाम /Patient's Name Vaibhav Kumar आयु / Age 14 लिंग /Sex M
(साफ अक्षरों में / In Block letters)

जन्म तिथि /Date of Birth : दिन /Day माह /Month वर्ष / Year वजन /Weight कि. ग्रा. /kg

4. General Patient Condition (Tick as appropriate)
(i) Critical and with life support (ii) III but without life support (iii) Ambulatory [checked]

5. Clinical Details : History :

Examinations:

Ⓛ Exophthalmos + squint ⊕
Ⓡ inferior retinal mass ⊕

Relevant Investigations :

Ⓛ large mass occupying vitreous cavity
? Retinoblastoma

Previous CT / MR / Other Reports / Studies

(with numbers, if any)

6. Blood Urea / S Creatinine

7. Clinical Diagnosis : MRI (Brain + orbit) 2mm cuts through optic nerve +
intraorbital gland fat suppressed contrast enhanced Axial
Coronal
Sagittal
sections

Exact Anatomical site for MRI

Special Instructions (Sedation, Allergy or other details which may facilitate a safe and informative study).

10 (a) Contrast Enhancement Required : Yes No

(b) Allergic to any drugs :

(c) Implant in Body (Tick as appropriate)

Cardiac Pacemaker Aneurysmal clips Cardiac Valve/Prosthesis

Metallic Implants Sharpnel/Pellet Others None

हस्ताक्षर / Signature

नाम / Name

(साफ अक्षरों में / In Block letters)

पदनाम / Designation

(Requisition may be signed by a Faculty Member/Sr. Resident)

DA: 11/2/26
OTHER:
NPO X 6 HOUR
RFT (JREAS, CHEATLINE)
WITHIN 1 WEEK
PAYMENT @ 7%
SIGN JRD

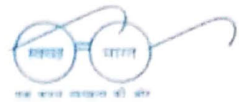डॉ. निरंजिता सोनी / Dr. NEEMTE LOMI
अतिरिक्त / Additional Professor
डॉ. आर.पी. सोनी / Dr. R.P. Soni
अतिरिक्त / Additional Professor
अध्यक्ष / Head
ऑप्टिकल / Optic
अध्यक्ष / Head
ऑप्टिकल / Optic
अध्यक्ष / Head
ऑप्टिकल / Optic

Dr. SANKU
Professor
Dr. P. ...

mso to help
MRI urgent
60g week



अ० भा० आ० सं० अस्पताल / A.I.I.M.S. HOSPITAL
बहिरंग रोगी विभाग / Out Patient Department



अस्पताल के अन्दर धूम्रपान करना है। / SMOKING IS PROHIBITED IN HOSPITAL PREMISES

घात चिकित्सा विभाग,
UHID:108769728

कमरा / Room
C 218
Queue / संख्या
F37
Unit-III, Paediatric

OPR-6



Dept No: 20250030032853

वैभव कुमार / VAIBHAV KUMAR

S/O VUJAY NARIT
17 DM 280 / भा.पुर.पं.
DIST DEOGARH, JHARKHAND, INDIA

बुध रोज, Wed Sat

करोड़ों में पंजीकृत नं./O.P.D. Regn. No.

आयु Age	पता / Address

General Re 0
Follow Up Patient



Reporting: 10:47:30
24/12/2025

भिदान / Diagnosis

B/LC RB ← (R) GP B
(L) GP E

दिनांक / Date

उपचार / Treatment

Test 1st HOCV - B/LC - 14/12/25
D+11

was seen in ER - for AGE - i dehydration
requiring correction
on zinc / amoxic / ofinone

GUNJAN KUMARI
Molten

HIV - NR

dent / nit complaints

LEMRI - Baseline : done on 22/12/2025

inc -

(R) nasal aspect - Small enhancing lesion
ON - non-enhancing
no coats crabs

(L) > 80% of globe involved
Inflammatory Spt count (+)

(Test Sptal) in Superior labial aspect



CLEAN AND GREEN AIIMS / एम्स का यही सकल स्वच्छता से काया कल्प
अंगदान-जीवन का बहुमूल्य उपहार / ORGAN DONATION - A GIFT OF LIFE
O.R.B.O., AIIMS, 26588360, 26593444, www.orbo.org Helpline - 1060 (24 hrs service)



no ON enhancement
no coats track
no involvement of parotid gland

Plan:

- 1) Syg. zinc (20mg/5ml) ~~20~~ 5ml OD x (week) mne
 - 2) Re-discontinuation of mne
 - 3) Syg. Septivan (40mg/5ml) 5ml PO A/D.
- 7) N/O - 27/12/2015

CBC
- RF-7
RF-7 } (B1)

Re-discontinuation - Dr. VISHAKHA / NIAHHA SINGH

POC - File - Date - 5/1/26.

Mujaji

Monday 2pm
with all photocopies.

Dr. SHARAN SHANUBHOGUE
Senior Resident-DM
Pediatric Oncology
Department of Pediatrics
AIIMS, New Delhi-29

ब० रो० वि० कार्ड O.P.D. Card



नेत्र अपुत्र उपहार है
जो आप ही दे सकते है

अनुभाग व दिन
Section and Day **IV**
सोमवार व बृहस्पतिवार
Monday & Thursday

कमरा नंबर
Cabin No.

डा० राजेन्द्र प्रसाद नेत्र विज्ञान केन्द्र
अ० भा० २

Dr. Rajen
A.I.I.M.S.



UHID: 108769728
AEHA
Dept No. 2025050140310

भरती / Queue: 9
कमरा / Room: 43
Unit IV
RPG OPD

यू०एच०आः
UHID N

वैभव कुमार / VAIBHAV KUMAR

Dr. Bhavna Chawla

रोगी
Name

SOMVIJAY NARIT
BYEMAD / M / 30
DISEASE: CGARRH INARKHANO 2026

MON THU
OPD



Dist: 9 3125 7273 General Es 0
Follow Up Patient

Registration time:
02/02/2026 09:51:35 AM

पता
Address

26A

दिनांक
DATE

निदान
DIAGNOSIS

उपचार Treatment

02 FEB 2026

Vnt 6/48
Gannat
25/26
cardist

Ad

continuous chemotherapy

- ECA after 4th cycle

DIF ECA after 4 weeks

37A or stage 14

Dr. Chawla

14 20/26
5th floor
7:30 AM

कृपया इस कार्ड को सुरक्षित रखें तथा अस्पताल में दिखाने के समय हर वक्त साथ लायें।

Kindly keep this Card safely and bring it on your follow-up visits.

- धूम्रपान निषेध 1. No Smoking
- कूड़ा कर्कट केवल कूड़ेदान में ही डालें 2. Use Dustbin
- थूकिये नहीं 3. No Spitting

(L) | E/d IObet ^{0.25'} (2)
 E/d. curc 0.5' (4)
 E/d. moni (4)

13/2/2026

URGENT

D/O EOA-14/2/2026 (Saturday)
 7th Floor RPC @ 7:00AM
 NPO explained

- solid (8hr) → 12AM
- broth (4hr) → 4AM
- liquid (6hr) → 2AM
- clear fluid (2hr) → 6AM

→ to assess for ^(R) brucation post ● CVA

[Signature]
 Dr. Tannay

नेत्र ईश्वरीय सर्वश्रेष्ठ उपहार है जिनका मनुष्य जीवन में दान करना परमश्रेष्ठ है।

इनकी पूर्ण रक्षा कीजिए ताकि ये आपकी रक्षा कर सकें।

Eyes are God's most precious gift to man kind and eye donation is the most noble deed.

Take full care of them so that they can take care of you.

14/2/2026

Report 142B
Nithinji

14/2/2026


ERA done by Dr N. Lomul / Dr Sumit
goverd
Dr Shife

s/p 3 cycles of chem
Ph clo
R Regressing gap BKB
L group ERB

Last Chem:

2 weeks ball

[30-31 Jan]



Last B USG: ~~USG machine malfunction~~
↳ mass in superolateral aspect
↳ calcified @
↳ reduced in mass

Adv
Bl 2 x 7 days
#143 Monday qm for
Epim or L Emulsion

Prog. Branna open:

OPD: 43

Mon / Thu

9:00 AM

USIB Prof Bhavna June 4 - OPO (43)

16/2/26

Ⓜ representing GP & RB

Ⓜ GP ERB

Ad

Interim chemotherapy - 4th cycle

- D/F admission after 4th cycle

Dr Shyams
3TB

Ⓜ Erylate
+

Ⓜ EOA

Dhaul

cardiff - 21/2/26

✓ 6/48 @ 50cm

NOT follow

cards

40 waiting Ⓜ

Ⓜ DOA - 11/3/26
Wanted DA, 7:30 AM
8:00 AM
2nd floor

- Ⓜ E10 1000 Ⓜ
- E10 Vigamox Ⓜ
- E10 Acupol 720 - 0.50
- E10 HA 24 Ⓜ
- E10 imco. 5x Ⓜ 2 weeks

Refer to Paeds oncology New RAK 2nd floor

209, 210, 211 - Dr Aditya / Prof Ramesh

Dr Jagdish - for 4th cycle

(Wed / Sat 9-1 PM)

chemotherapy

↓

Flu after 4th cycle


on for D/F admission

28/1/26

B/L IO RB — (R) Grp B Rb
(L) Grp E Rb

- oral Carrē
- Sitz bath
- personal hygiene.
- on septran. A/D.

2nd HDCEV received on 4/1/26



No fever
No bleeding
No irritability/
crying

LFT/RFT - WNL

D₁ - 30/1/26 ^{advised}
D₂ - 31/1/26

Adv.

- Due for Cycle 3 #

- Premedicate \bar{c} Inj Emset 2mg IV STAT

DL - Inj VCR 0.2mg IV slow push

DL - Inj CARBOPLATIN 250mg / 100ml NS IV
over 1 hour

(D₁ - D₂) Inj ETOPOSIDE 110mg / 300ml NS IV
over 2 hours

(~~D₃~~ - ~~D₇~~) - Inj 9-CSF 45mcg SC OD

chemo date - chemotherapy to be given in daycare ^{at 1st}

30/1/26 - RB gene testing advised

31/1/26 - Vision assessment of left eye to be done today in RBC OPD for plan of Enucleation

- Tab Emset 2mg 1/2 tab⁸ PO ~~bid~~ x 2 days

- Tab Dexa 1/2 tab 2mg PO OD x 3 days

DG @
4/2/26
B- 12/11/26



Adv.

11/2/26

Bilateral IORB.

- (R) GIPB. (unrelief to coal)
- (L) GIPB



post 2# EUA.
↳ Regress (R)

post 3# HDCEV ∴ 31/1/26

Due for #4 on/after 2/2/26

6.2 } 5360 } 90000
 } 250 }
 LFT/RFT - OK

No fresh complaints

EUA FU dated 7/3/26

Recheck fresh
CBC before
next #

Adv.

- Take #4 date
- To plan (L) evacuation
↓ RPC

• Prechemo

- Iy. Dexa 2y + Emeset 2y IV

• chemo

- Iy. VCR 0.2 y IV push

- Iy. Carboplatin 250y/100u/m²

- Iy. Etoposide 110y/500u/m² IV.

• post chemo

- Tab Dexa 2y OD | x30

- syp Emeset 5ml TDS | x30

- Iy. G-CSF 50 y SC OD
D_A - D₁₁

- FU c CBC, LFT/RFT on 7/3/26

9